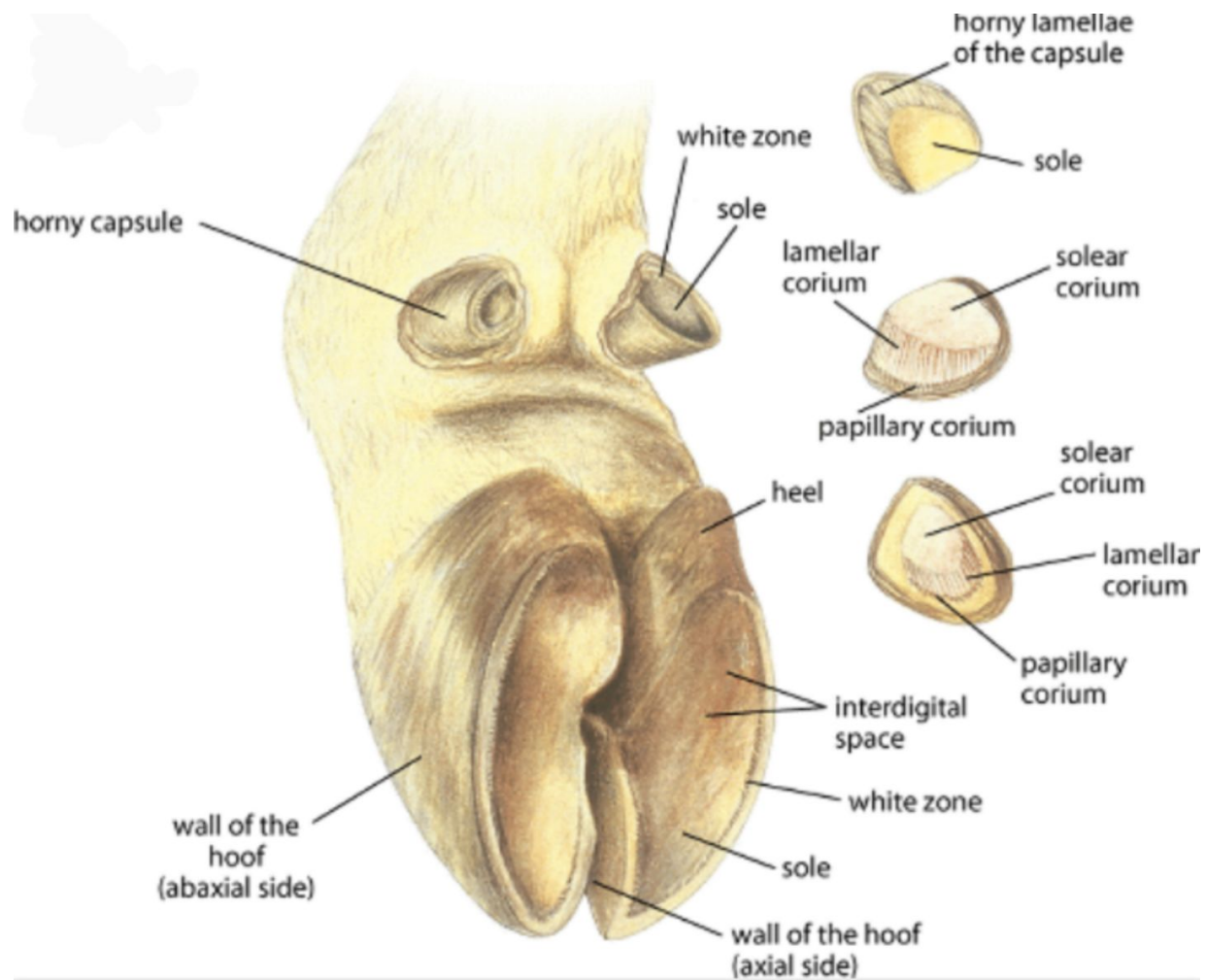
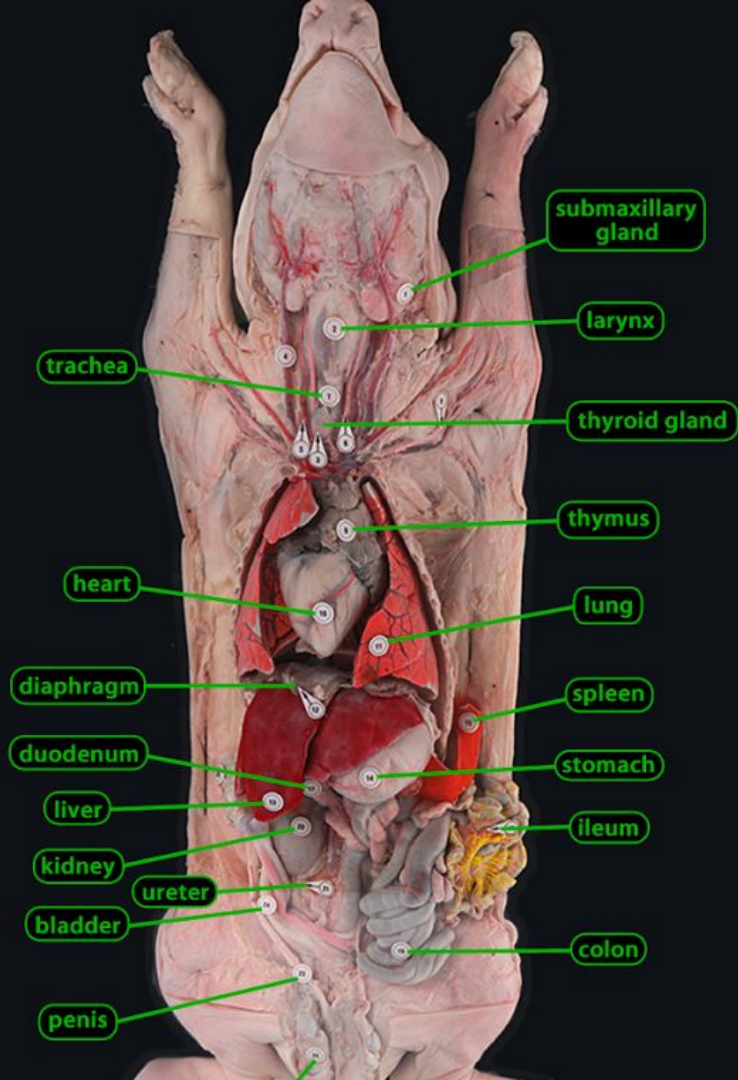
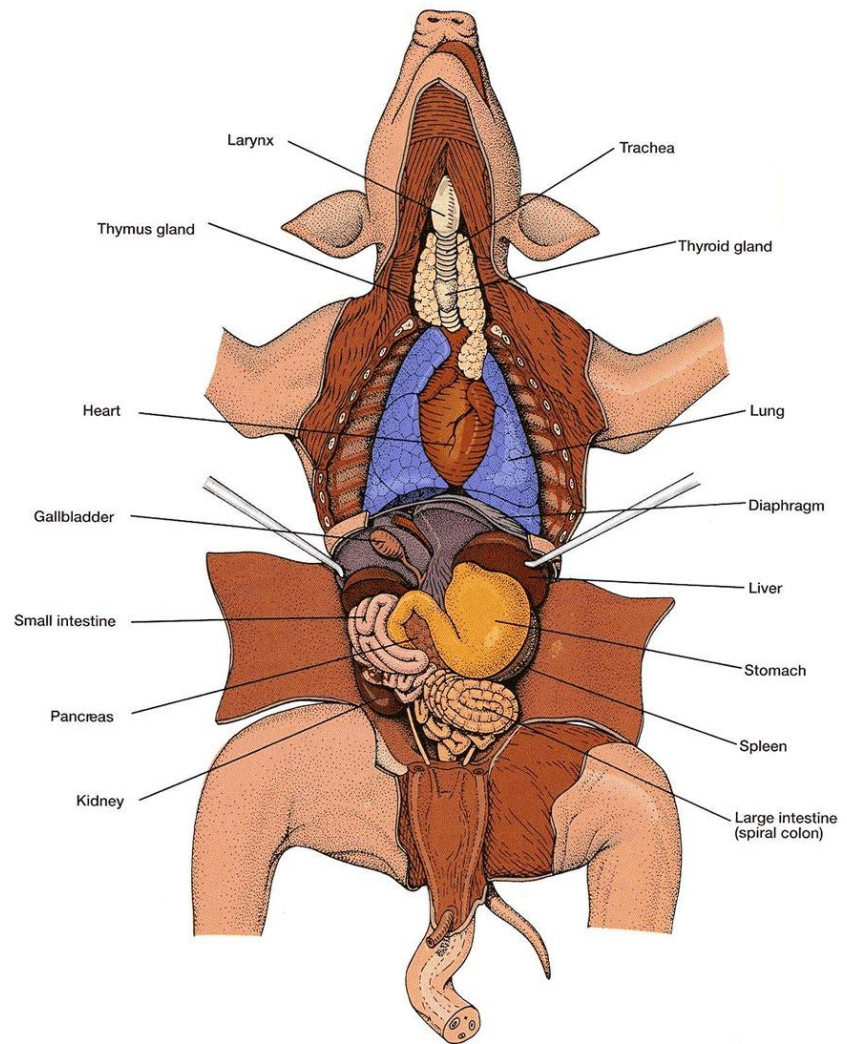
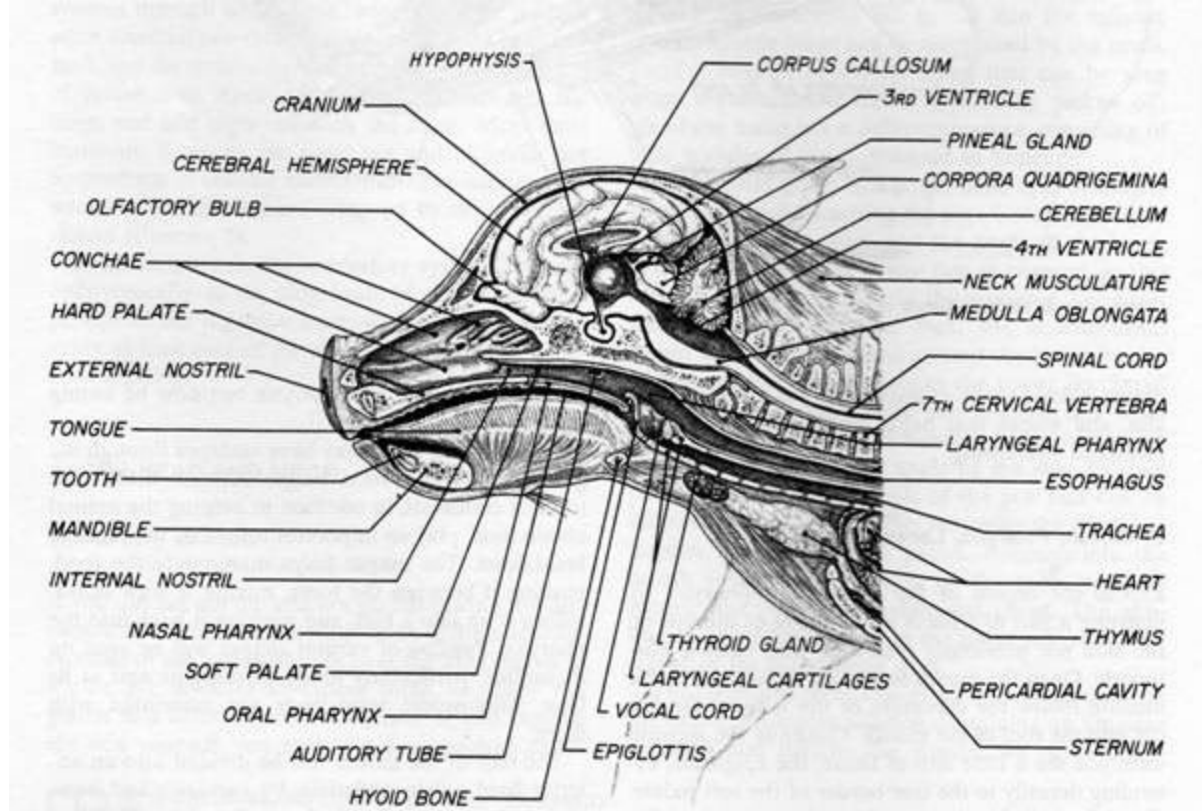


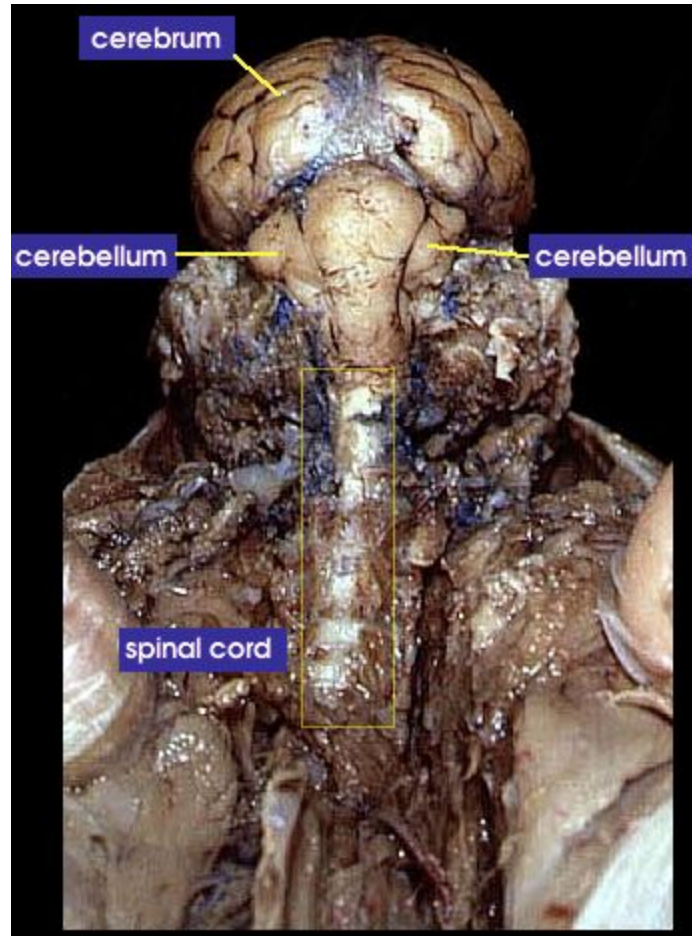
Visual Guides for the Fetal Pig Dissection



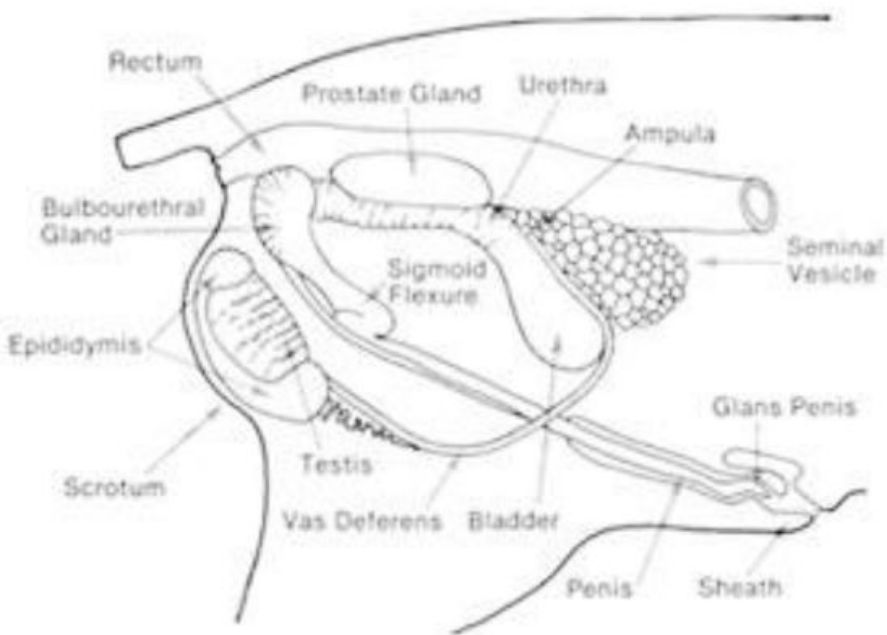




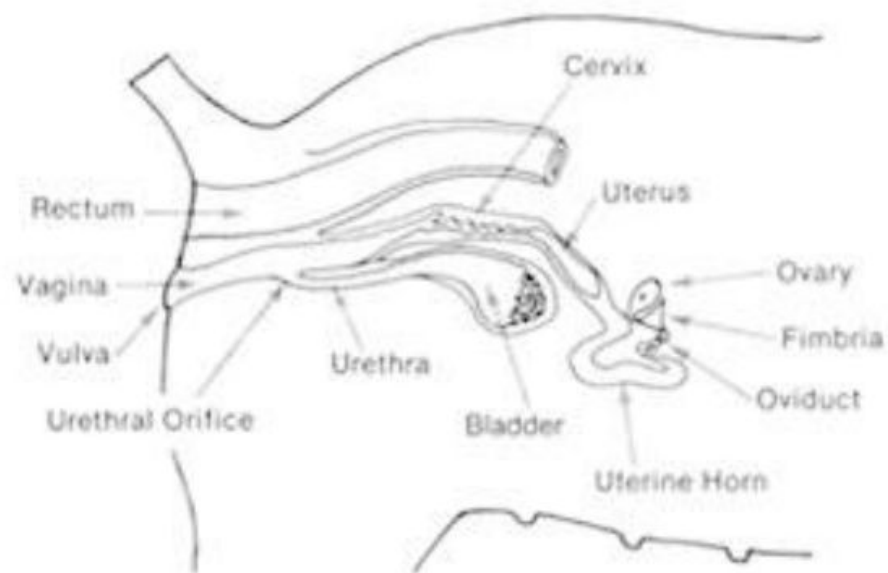


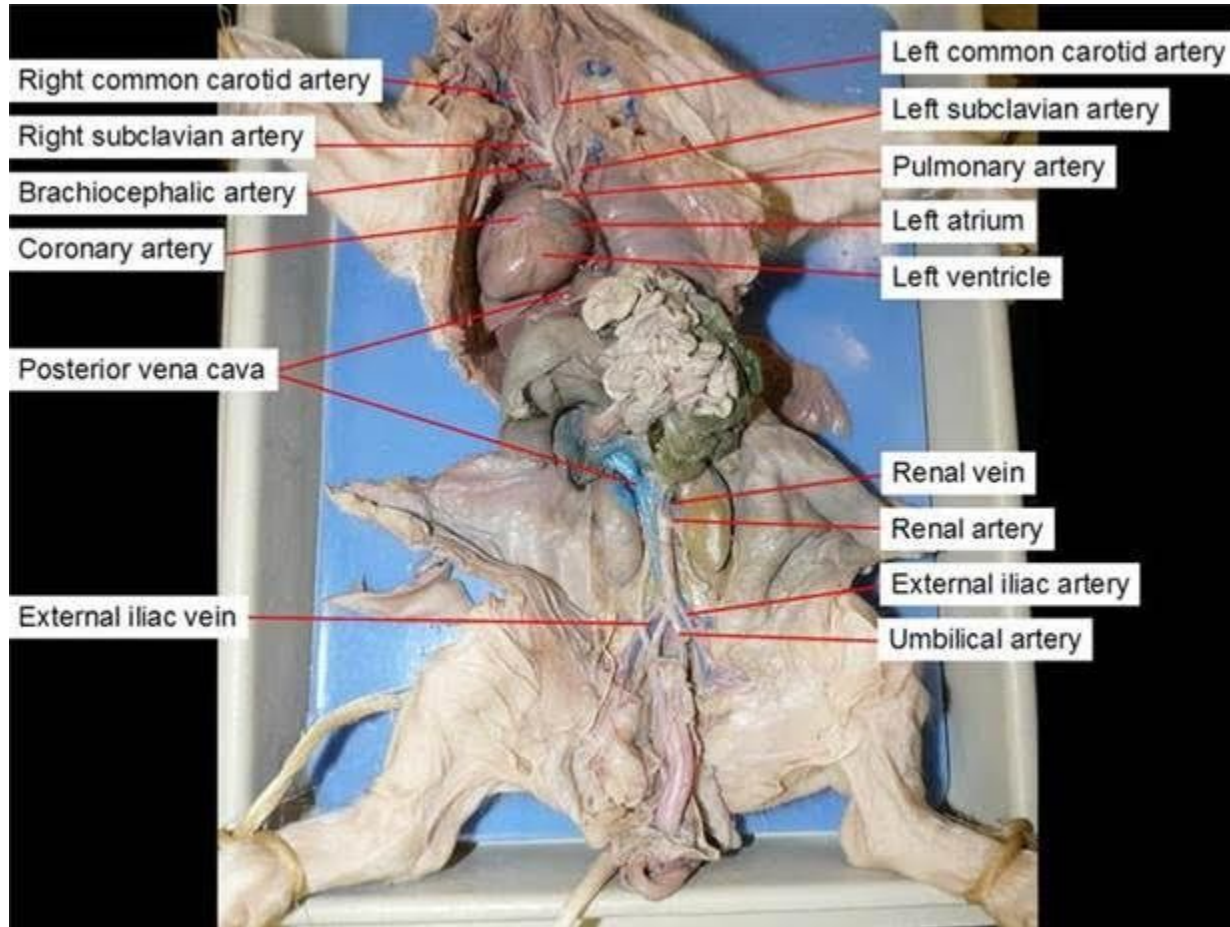


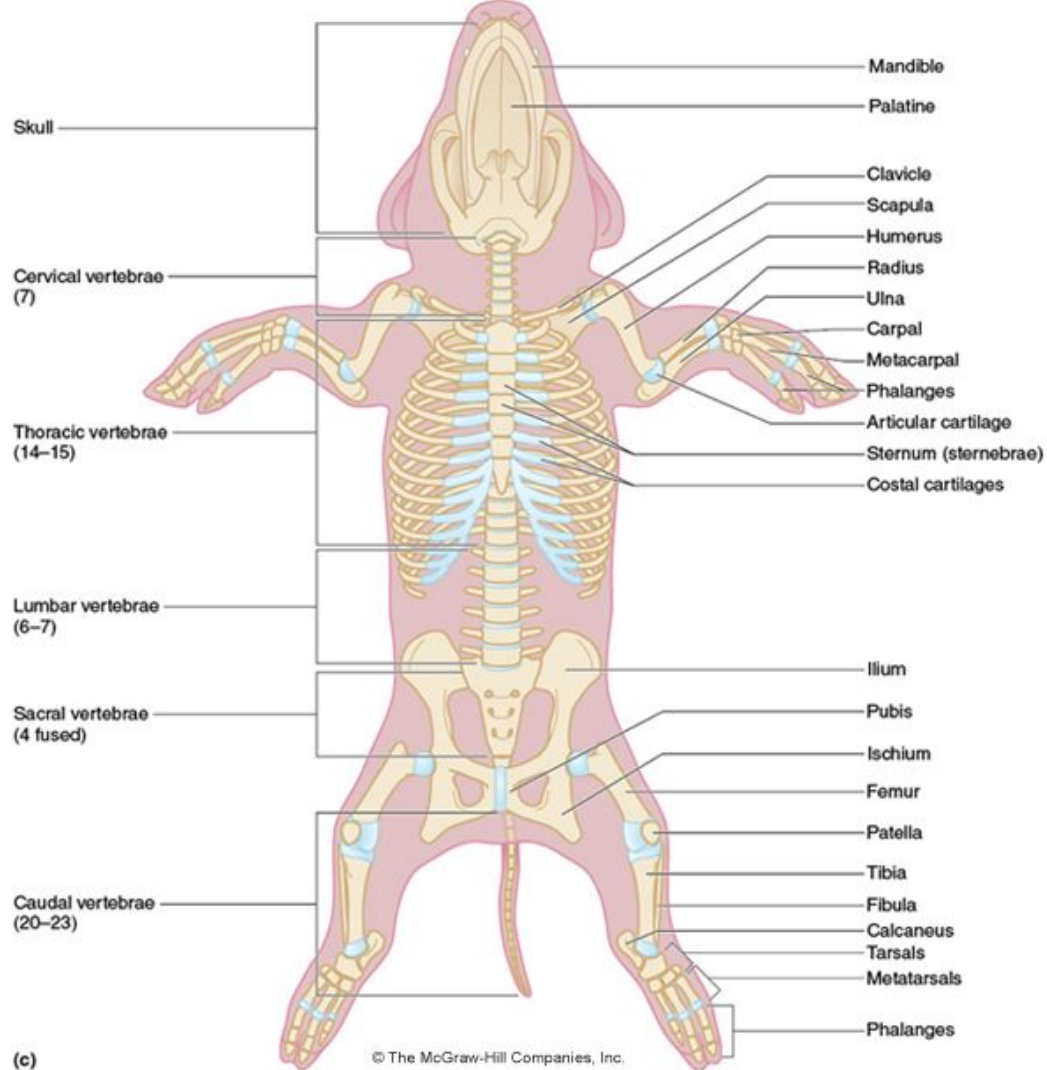
Male



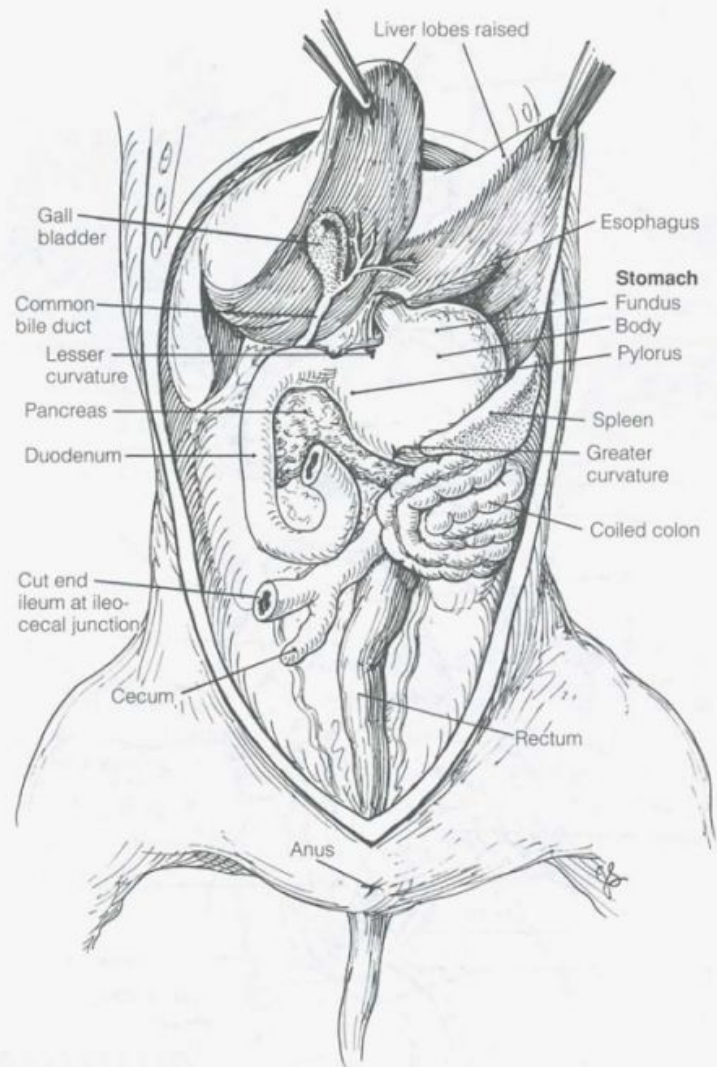
Female







(c)



Interior anatomy of the Pig heart

