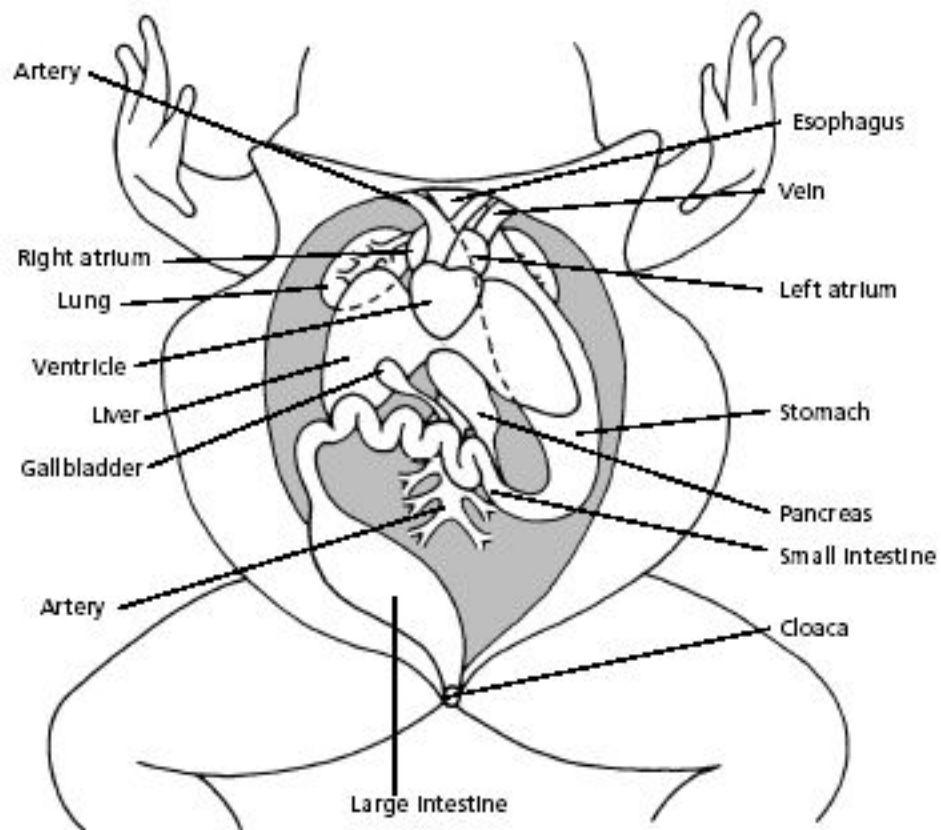
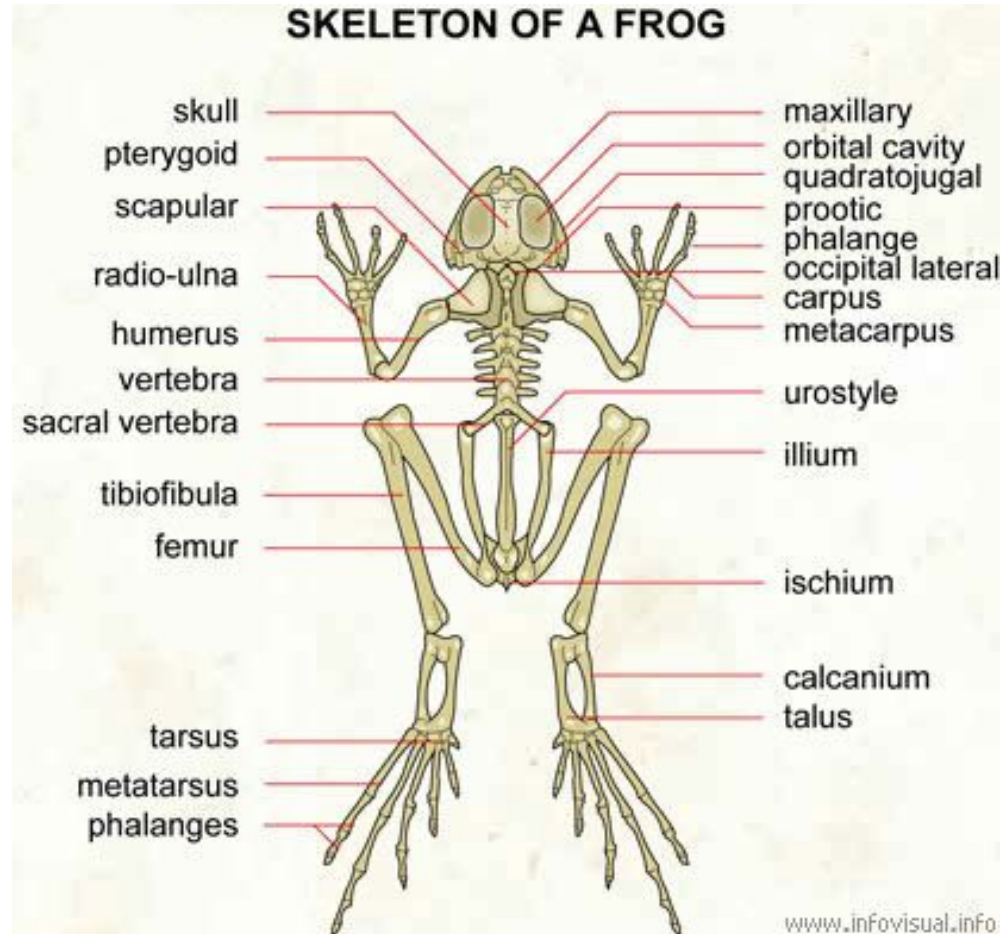


Frog Dissection Maps

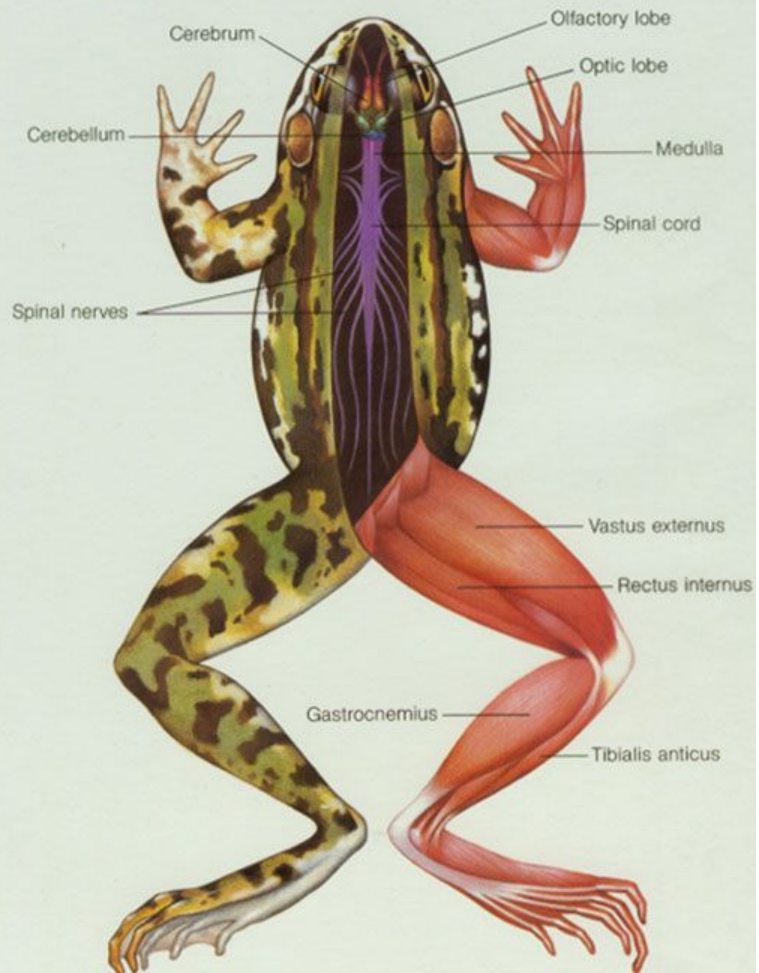
Abdominal and Chest Cavities of the Frog



Skeletal



41. The Nervous and Muscular Systems of a Frog



Nervous

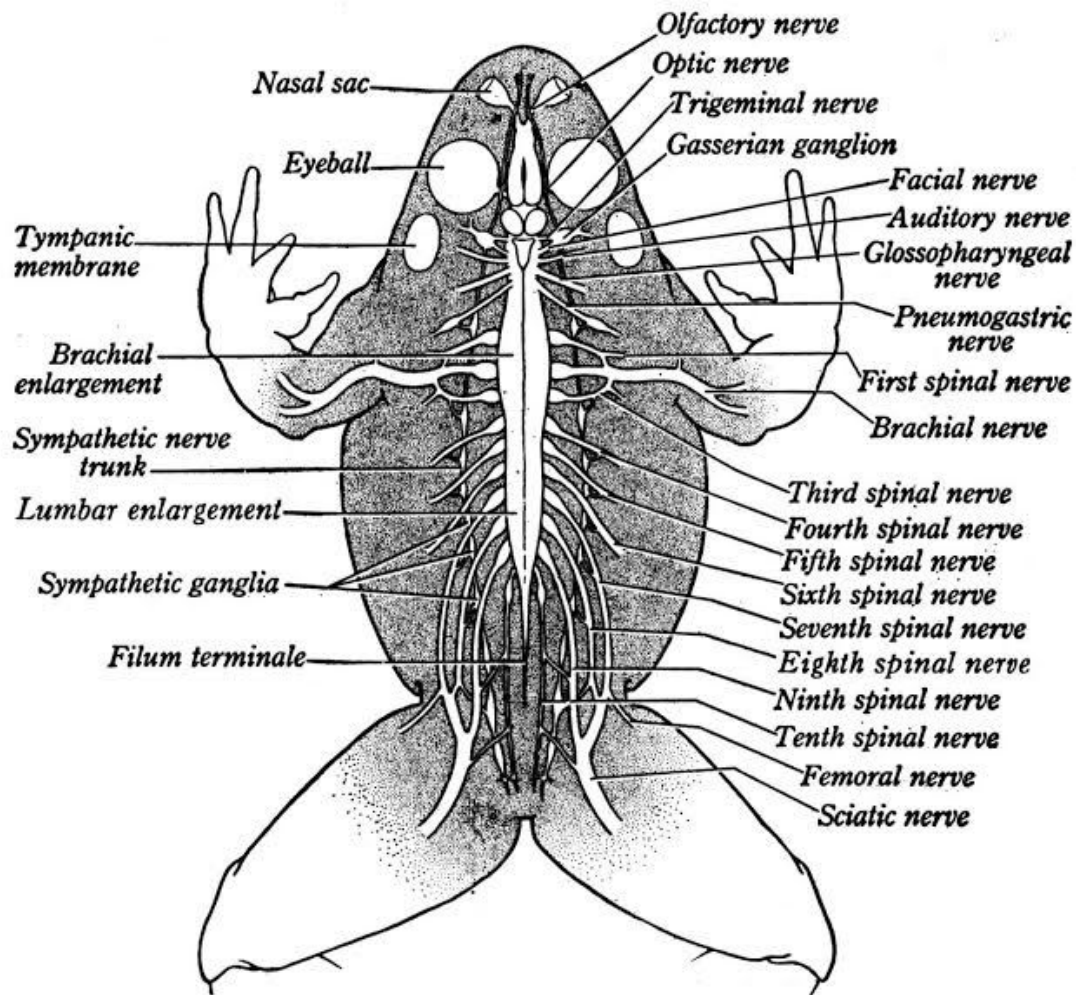


FIG. 408. Dorsal View of Nervous System of Frog

Muscular

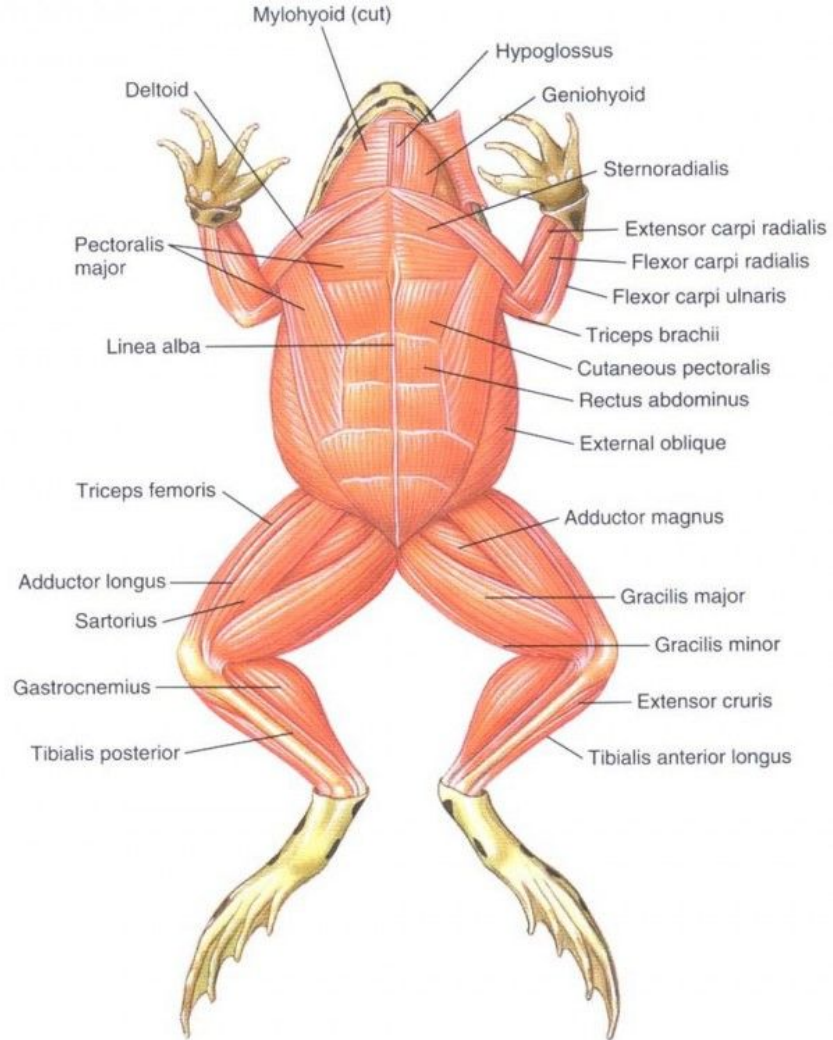
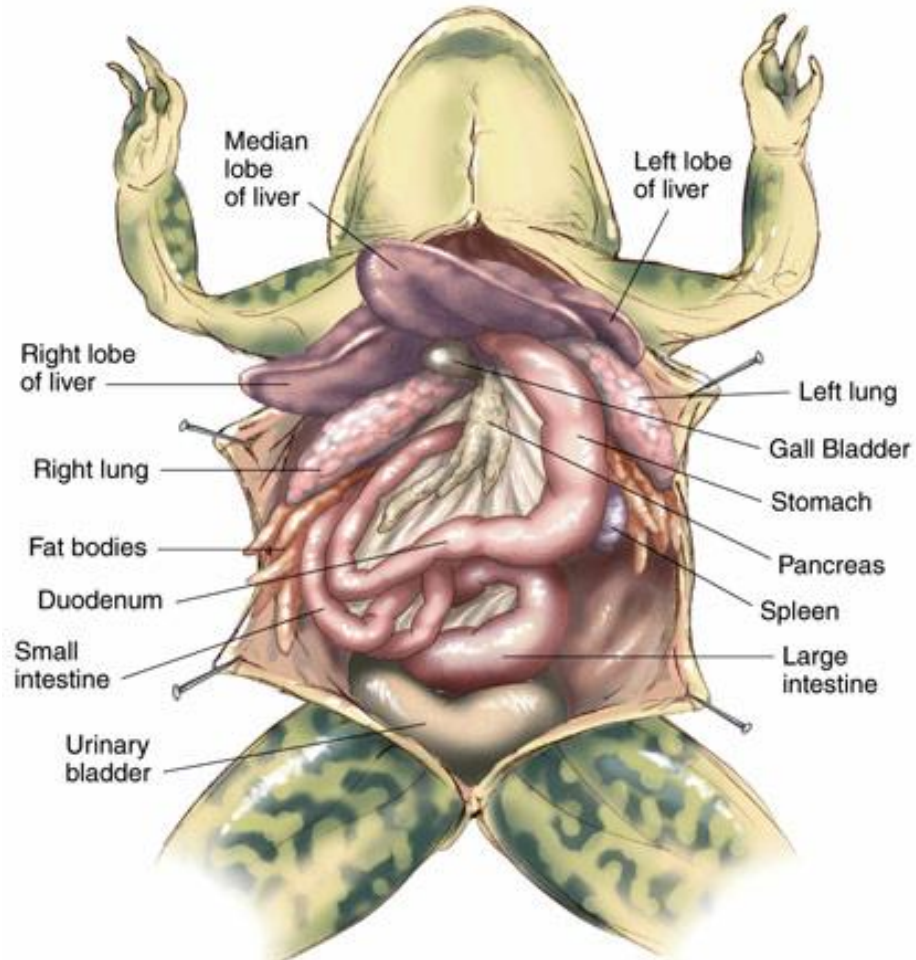


Figure 19-4

Digestive



Skin



4G



82%



9:48 AM

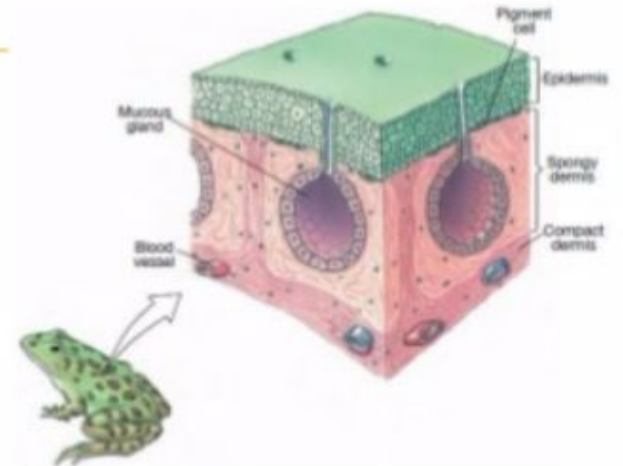
Brief description of vertebrate skin

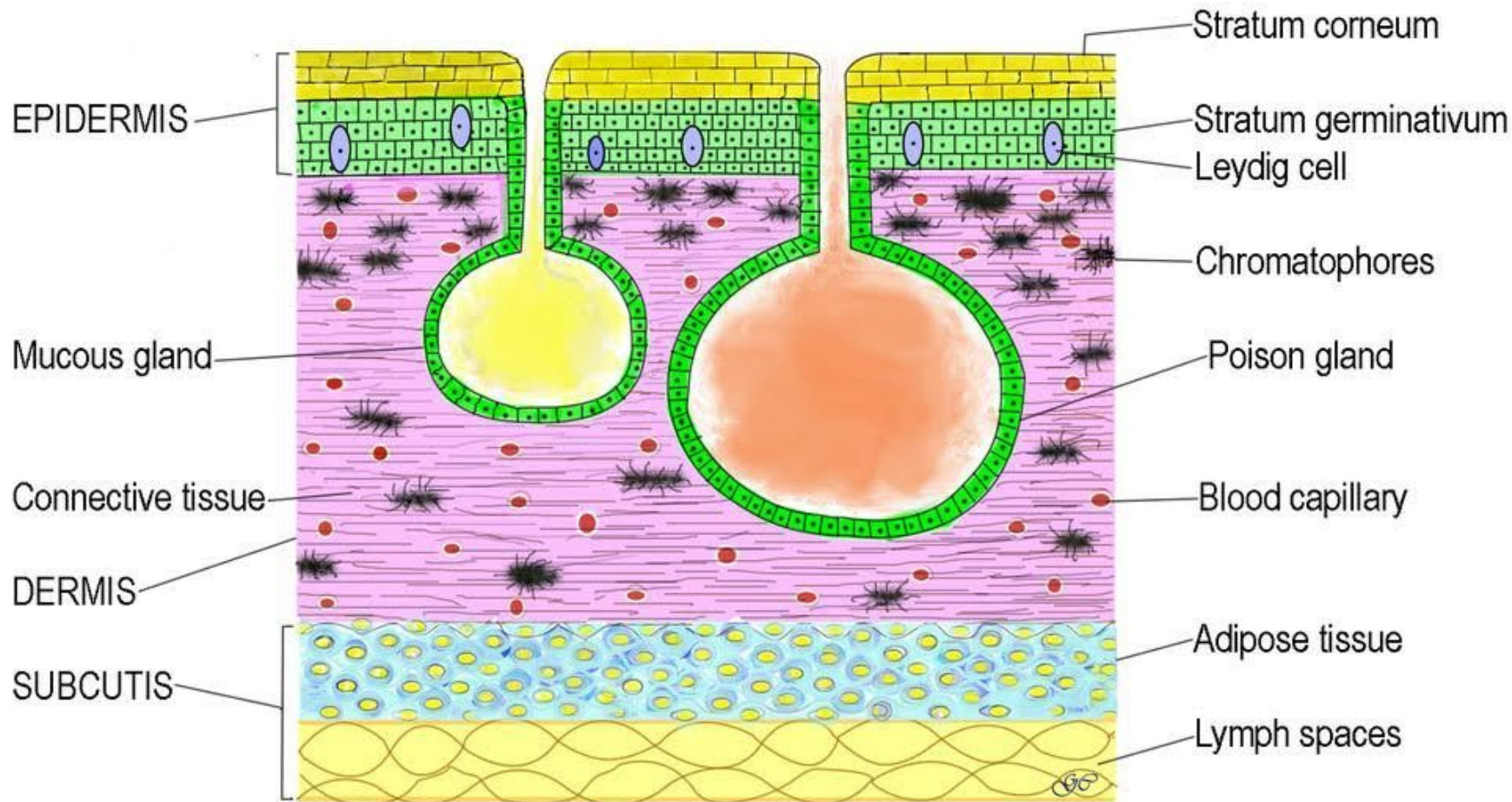
Land vertebrates (amphibians, reptiles birds and mammals)

have a **stratified epidermis** of several cell layers with the outermost portion cornified.

Amphibians

- its skin is glandular and moist; thin and naked
- for respiration and absorption





VERTICAL SECTION OF SKIN OF FROG

42. The Reproductive Systems of a Female and a Male Frog

